

Stimulation of human somatosensory cortex: tactile and body displacement perceptions in medial regions

Francois Richer^{1,2}, Meritxell Martinez^{1,2}, Manon Robert^{1,2}, Guy Bouvier^{1,3}, Jean-Marc Saint-Hilaire^{1,3}

¹ Unité d'Epilepsie, Hôpital Notre-Dame, Montréal, Québec, Canada

² Université du Québec à Montréal, Québec, Canada

³ Université de Montréal, Montréal, Québec, Canada

Received: 22 June 1992 / Accepted: 16 October 1992

Abstract. We examined the somatosensory perceptions evoked by stimulation of rolandic and parietal brain regions in 40 epileptic patients undergoing a presurgical investigation with intracerebral electrodes. Bipolar stimulation trains were delivered in an incremental sequence at medial and/or lateral contact pairs of stereotaxically implanted, multi-contact electrodes, while monitoring stimulus afterdischarge propagation with electrodes in frontal and temporal lobes. Rolandic stimulation evoked contralateral sensations, whereas sensations from either side were evoked in the opercular region. Stimulation of lateral posterior parietal cortex evoked only few sensations and these were restricted to the supramarginal gyrus. Contralateral sensations were evoked in the posterior cingulate gyrus, whereas ipsilateral sensations were evoked in the vicinity of the cingulate sulcus. Complex proprioceptive sensations in the form of bilateral feelings of levitation were elicited in a medial parietal region around the subparietal sulcus and not at any other site. These perceptions were not accompanied by any movement, tactile, or vestibular sensations, suggesting that the human sub-parietal sulcus region is linked to the proprioceptive processing system.

Key words: Somatosensory cortex – Brain stimulation – Body position sense – Parietal cortex – Human

Introduction

The parietal lobe of primates contains several distinct somatosensory regions. The areas in the post-central gyrus (3,1, 2 or SI) and the parietal operculum (SII) are the best investigated in both monkeys and humans (Kaas et al. 1981; Penfield and Jasper 1954; Penfield and Rasmussen 1950; Powell and Mountcastle 1959; Randolph

and Semmes 1974; Woolsey 1958). Somatosensory areas can also be found dorsal (PE, PEc, PEci, PEa, PGm) and ventral (PF, PFG) to the intraparietal sulcus (Jones and Powell 1969; Pandya and Seltzer 1982).

Some functional differentiation has been possible for areas outside of SI and SII (Hyvarinen 1982; Lynch 1980). Dorsal to the intraparietal sulcus, a large proportion of neurons respond to passive joint movement (Duffy and Burchfiel 1971; Hyvarinen and Poranen 1974; Mountcastle et al. 1975; Sakata et al. 1973, 1978). Data from parietal lesions in non-human primates show deficits in several submodalities of somatic perception, but strong regional differentiations have not yet been revealed (Lamotte and Mountcastle 1979; Moffett et al. 1967).

In humans, parietal damage can cause several somatosensory deficits, including problems of form identification, the perception of limb position or body shape, attention to stimuli or portions of the body, tactile localization or discrimination, as well as changes in sensitivity for one or many somatosensory dimensions (Corkin et al. 1970; Critchley 1953; Dejerine 1907; Denny-Brown and Chambers 1958; Hecaen and Albert 1978; Semmes 1973; Semmes et al. 1960). However, no clear functional differentiation of somatosensory cortex has yet been revealed in humans.

We have studied the regional differentiation of human somatosensory cortex using the effects of localized intracerebral stimulation on tactile and proprioceptive perceptions in epileptic patients undergoing a presurgical investigation.

Materials and methods

The intracerebral stimulation protocol was part of a presurgical investigation of patients with pharmaco-resistant epilepsy which included scalp and intracerebral recording of seizures, as well as neuroradiological and clinical measures (Saint-Hilaire 1987). The goal of intracerebral stimulation was to try to reproduce the first symptoms of seizures as a further localization measure (Bernier et al. 1990). Informed consent was obtained according to normal hos-

Correspondence to: F. Richer, Laboratoire de Neurosciences, Département de Psychologie, Université du Québec à Montréal, Box 8888, Montréal, Québec, Canada, H3C 3P8

pital procedures after explaining to the patients the nature, goals, and possible consequences of the stimulation procedure. Intracerebral electrode locations were selected on the basis of clinical considerations. All patients with at least one electrode in perirolandic or parietal cortex who had undergone cortical stimulation in the last 15 years were selected for this study. Stimulation was delivered at 80 sites in 40 patients.

Multilead electrodes were implanted stereotaxically in a latero-medial axis using teleradiography and a modified Talairach frame (Bouvier et al. 1987). Electrode location was determined from post-implantation coronal and sagittal radiographs referenced to the Talairach atlas (Talairach and Szikla 1967; Talairach and Tournoux 1988). Between one and three posterior electrodes and between four and nine electrodes in frontal and anterior temporal brain areas were implanted in each case.

At each electrode, medial and/or lateral pairs of contacts (0.8 mm radius, 1.8 mm length, 5 mm apart) were stimulated in a bipolar fashion. At each site, five to ten stimulus trains of 5 s each were delivered in an incremental sequence (1–10 mA) with a minimum delay of 55 s between consecutive trains. The stimulus trains consisted of biphasic pulses of 0.5 ms each delivered at 50 cycles/s. The stimulation sequence was discontinued when either: (1) a neuroelectric afterdischarge was induced at more than one site; (2) a seizure was evoked or (3) a charge density of 7.5 $\mu\text{C}/\text{cm}^2$ per phase was

reached. This procedure evokes few phenomena and few diffusions of electrical afterdischarges from one structure to another. Patients were asked to report any symptom felt during the session and were unaware of the time of delivery of stimulations. Only phenomena that were not accompanied by afterdischarges at any site outside of the stimulated site were considered.

Results

Somatosensory phenomena were evoked at 19 of the 80 stimulation sites as illustrated in Fig. 1. Only one patient, who had three electrodes in the parietal region, reported more than one tactile sensation. Non-somatosensory phenomena evoked included movements (with stimulation of perirolandic and posterior cingulate regions), visual sensations (precuneus and angular gyrus), auditory sensations (superior temporal gyrus) and sensations of dizziness (posterior cingulate).

Twenty-one sites were stimulated in perirolandic regions laterally in the pre- and post-central gyri or dorso-

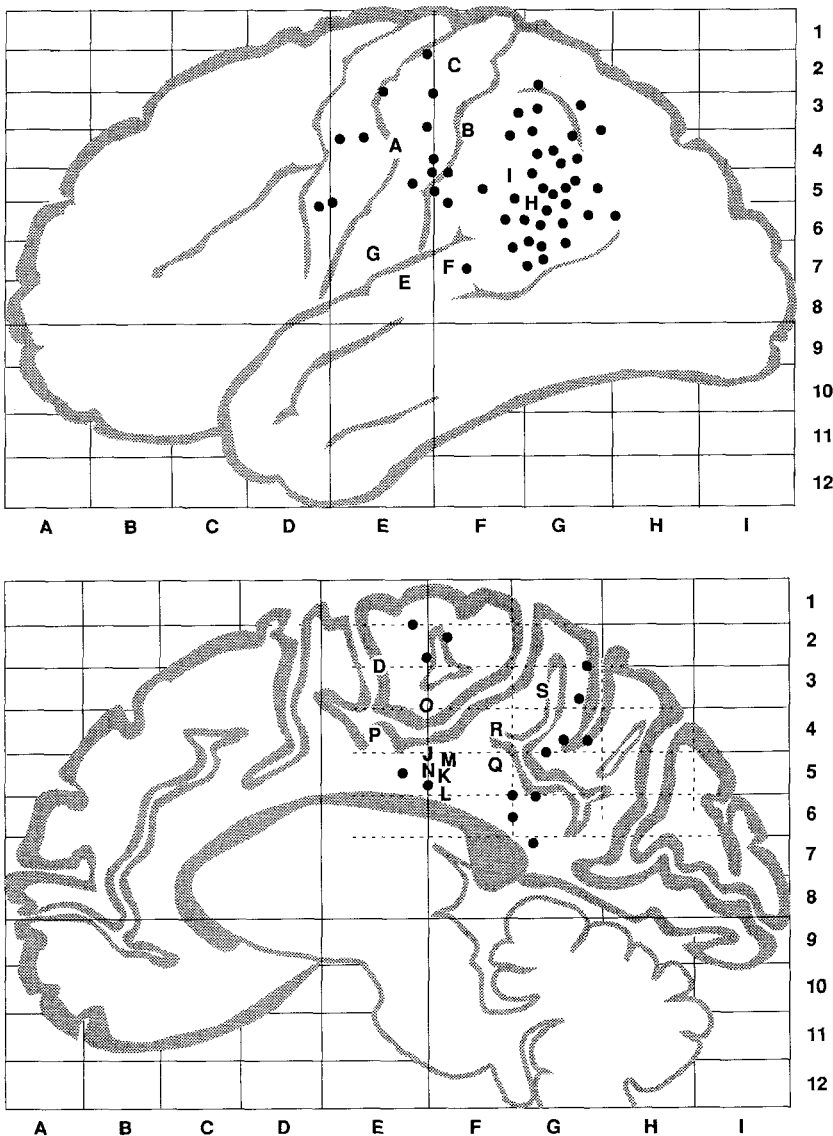


Fig. 1. Lateral view (above) and medial view (below) of the normalized brain in the proportional stereotaxic coordinate system of Talairach showing the positions of the electrodes stimulated. The medial view is approximately 1 cm from the midline. Letters mark sites at which somatosensory phenomena were evoked. The locations of sulci and other landmarks are approximate

medially in the paracentral gyrus. Laterally, sensations to the contralateral hand (A in Fig. 1) and arm (B) were evoked in the post-central gyrus. Dorsomedially, evoked sensations involved the contralateral back (C) and leg (D).

Four sites were stimulated in the sylvian or opercular regions, most of them situated at the level of the posterior superior temporal gyrus. Somatosensory responses included a bilateral sensation in the back (E), a sensation in the contralateral hand (F), and a sensation in the ipsilateral leg (G).

Thirty-seven sites were stimulated in lateral posterior parietal cortex of which it was estimated that 26 were in the supramarginal gyrus, seven were in Brodmann area 7, and four in the angular gyrus. In this region, stimulations were rarely positive. Sensations in the contralateral arm (H,I) were evoked by stimulation in supramarginal gyrus, but no other sensation was evoked at any other site.

Seven sites were stimulated in the posterior cingulate gyrus ventral to the paracentral lobule. Five of these seven sites were positive, evoking contralateral sensations in the foot (J,K), leg (L), back (M), or hand (N). Two sites (P,O) were located dorsal to the posterior cingulate group in the vicinity of the marginal branch of the cingulate sulcus. Stimulation of these sites evoked sensations in the ipsilateral hand (O) and back (P).

Twelve sites were stimulated in medial parietal regions. Simple somatosensory responses were not evoked at these sites. However, at three sites (Q,R,S), stimulation evoked perceptions of altered body position. In the three cases, the electrode was situated in the vicinity of the sub-parietal sulcus. Two of these sites (Q and R) were next to the horizontal portion of the sulcus, adjoining the posterior cingulate, the third site (S) was next to the vertical portion of the sulcus, adjoining the cingulate sulcus. Patient Q reported feeling his legs and seat floating above the bed. Patients R and S reported feeling their whole body floating just above the bed. The body displacement phenomena were not accompanied by any movement, nor did the patients report any other sensation, dizziness or any alteration of consciousness. These perceptions were replicated at higher current density in the three patients.

Discussion

These stimulation data confirm the previously established distinctiveness of lateral somatosensory regions in rolandic, opercular, and supramarginal cortex (Penfield and Rasmussen 1950). In addition, they suggest that medial central and parietal cortex contains distinct somatosensory regions in the central cingulate gyrus, the cingulate sulcus, and the sub-parietal sulcus.

Somatosensory responses in the posterior cingulate region seem to differentiate two sub-regions: one in or around the anterior portion of area 23 associated with contralateral sensations, and another in the banks of the cingulate sulcus in or around medial area 5 associated with ipsilateral sensations. The latter may be related to area PEci of the monkey, which lies in the banks of the

posterior cingulate sulcus, or to portions of what has been termed the "supplementary somatosensory area" (Murray and Coulter 1981; Pandya and Seltzer 1982). Physiological investigations of PEci may help to clarify this point.

The only complex responses evoked by stimulation were the modifications in the perception of body position in the region of the subparietal sulcus. These sensations were not accompanied by other phenomena, were unrelated to seizure symptoms of the patients or to the site of the epileptic focus, and were not evoked elsewhere. This suggests that the subparietal sulcus region of the human medial parietal lobe is associated with the proprioceptive processing system.

These evoked sensations of levitation bear some resemblance to some of the symptoms associated with parietal damage. Paroxysmal illusions of body displacement (mostly in the form of feelings of levitation) have been reported in association with parietal injury (de Ajuriaguerra and Hecaen 1960; Hecaen and de Ajuriaguerra 1952; Hecaen and Albert 1978). Parietal lesions also frequently cause a loss of position sense in the limbs (Dejerine 1907; Hecaen and Albert 1978), but the phenomena reported in paroxysmal illusions and by our patients are positive modifications in perception that involve large portions of the body.

The present data associate portions of the medial parietal cortex with proprioceptive information processing. This association agrees with the functional characterization of neighboring superior parietal lobule in the monkey, in which a majority of neurons respond to proprioceptive or kinesthetic signals. In the monkey, the medial parietal cortex contains area PGm, the most posterior of the dorsal stream of somatosensory association areas. This dorsal stream begins in dorsal area 2, and includes multiple areas (PE, PEc, PEci) in the superior parietal lobule (Jones et al. 1978; Vogt and Pandya 1978). This area projects to adjacent posterior cingulate as well as to premotor cortex and caudal superior temporal sulcus. The human subparietal sulcus region may bear some relationship to area PGm of the monkey, but neither human nor monkey medial parietal cortex has been investigated sufficiently to draw parallels between the two species.

Acknowledgements. The research was supported by grants from the Fonds de la Recherche en Santé du Québec and the Medical Research Council of Canada. We thank Drs. G. Bernier and N. Giard for use of the patient material and M. Mercier for assistance.

References

- Ajuriaguerra J de, Hecaen H (1960) *Le cortex cérébral*, 2nd edn. Masson, Paris
- Bernier GP, Richer F, Giard N, Bouvier G, Turmel A, Mercier M, Saint-Hilaire JM (1990) Electrical stimulation of the human brain in epilepsy. *Epilepsia* 31:513-520
- Bouvier G, Saint-Hilaire JM, Giard N, Lesage J, Cloutier L, Béique R (1987) Depth electrode implantation at Hopital Notre-Dame. In: Engel J (ed) *Surgical treatment of the epilepsies*. Raven Press, New York, pp 589-593
- Corkin S, Milner B, Rasmussen, T (1970) Somatosensory thresholds. *Arch Neurol* 23:41-58

- Critchley M (1953) The parietal lobes. Edward Arnold, London
- Dejerine J (1907) A propos de l'agnosie tactile. *Rev Neurol* 15:781–784
- Denny-Brown D, Chambers RA (1958) The parietal lobe and behavior. *Res Publ Assoc Res Nerv Ment Dis* 36:35–117
- Duffy FH, Burchfiel JL (1971) Somatosensory system: organizational hierarchy from single units in monkey area 5. *Science* 172:273–275
- Hecaen H, Ajuriaguerra J de (1952) *Méconnaissances et hallucinations corporelles*. Masson, Paris
- Hecaen H, Albert ML (1978) *Human neuropsychology*. Wiley, New York
- Hyvärinen J (1982) *The parietal cortex of monkey and man*. Springer, Berlin Heidelberg New York
- Hyvärinen J, Poranen A (1974) Function of the parietal associative area 7 as revealed from cellular discharge in alert monkeys. *Brain* 97:673–692
- Jones EG, Powell TPS (1969) Connexions of the somatic sensory cortex of the rhesus monkey. I. Ipsilateral cortical connexions. *Brain* 92:477–502
- Jones EG, Coulter JD, Hendry SHC (1978) Intracortical connectivity of architectonic fields in the somatic sensory, motor and parietal cortex of monkeys. *J Comp Neurol* 181:291–348
- Kaas JH, Sur M, Nelson RJ, Merzenich MM (1981) The postcentral somatosensory cortex: multiple representations of the body in primates. In: Woolsey CN (ed) *Cortical sensory organization*, vol 1. Humana Press, Clifton, NJ, pp 29–45
- LaMotte RH, Mountcastle VB (1979) Disorders of somesthesia following lesions of parietal lobe. *J Neurophysiol* 42:400–19
- Lynch JC (1980) The functional organization of the posterior parietal association cortex. *Behav Brain Sci* 3:485–499
- Moffett A, Ettlinger G, Morton HB, Piercy MF (1967) Tactile discrimination performance in the monkey: the effort of ablation of various subdivisions of posterior parietal cortex. *Cortex* 3:59–96
- Mountcastle VB, Lynch JC, Georgopoulos A, Sakata H, Acuna C (1975) Posterior parietal association cortex of the monkey: command functions for operations within extrapersonal space. *J Neurophysiol* 38:871–909
- Murray EA, Coulter JD (1981) Supplementary sensory area: The medial parietal cortex in the monkey. In: Woolsey CN (ed) *Cortical sensory organization*, vol 1. Humana Press, Clifton, NJ, pp 167–195
- Pandya DN, Seltzer B (1982) Intrinsic connections and architectonics of posterior parietal cortex in the rhesus monkey. *J Comp Neurol* 204:196–210
- Penfield W, Jasper HH (1954) *Epilepsy and the functional anatomy of the human brain*. Little Brown, Boston
- Penfield W, Rasmussen T (1950) *The cerebral cortex of man*. Macmillan, New York
- Powell TPS, Mountcastle VB (1959) Some aspects of the functional organization of the post-central gyrus of the monkey: a correlation of findings obtained in a single unit analysis with architecture. *Bull Johns Hopkins Hosp* 105:133–162
- Randolph M, Semmes J (1974) Behavioral consequences of selective subtotal ablations in the post central gyrus of *Macaca mulatta*. *Brain Res* 70:55–70
- Saint-Hilaire JM (1987) Presurgical evaluation protocols: Notre-Dame hospital. In: Engel J (ed) *Surgical treatment of the epilepsies*. Raven Press, New York, pp 675–676
- Sakata H, Iwamura Y (1978) Cortical processing of tactile information in the first somatosensory and parietal association areas in the monkey. In: Gordon G (ed) *Active touch: the mechanism of recognition of objects by manipulation*. Pergamon Press, Oxford, pp 55–72
- Sakata H, Takaoka Y, Kawarasaki A, Shibutani H, (1973) Somatosensory properties of neurons in the superior parietal cortex (area 5) of the rhesus monkey. *Brain Res* 64:85–102
- Semmes J (1973) Somesthetic effects of damage to the central nervous system. In A Iggo (ed) *Handbook of sensory physiology*, vol II Springer, Berlin, pp 719–742
- Semmes J, Weinstein S, Ghent L, Teuber H-L (1960) Somatosensory changes after penetrating brain wounds in man. Harvard University Press, Cambridge
- Talairach J, Szikla G (1967) *Atlas stéréotaxique du télencéphale*. Masson, Paris
- Talairach J, Tournoux P (1988) *Co-planar stereotaxic atlas of the human brain*. Thieme, Stuttgart
- Vogt BA, Pandya DN (1978) Cortico-cortical connections of somatic sensory cortex (areas 3, 1 and 2) in the rhesus monkey. *J Comp Neurol* 177:179–192
- Woolsey CN (1958) Organization of somatic sensory and motor areas of the cerebral cortex. In: Harlow HF, Woolsey CN (eds) *Biological and biochemical bases of behavior*. University of Wisconsin Press, Madison, pp 63–81